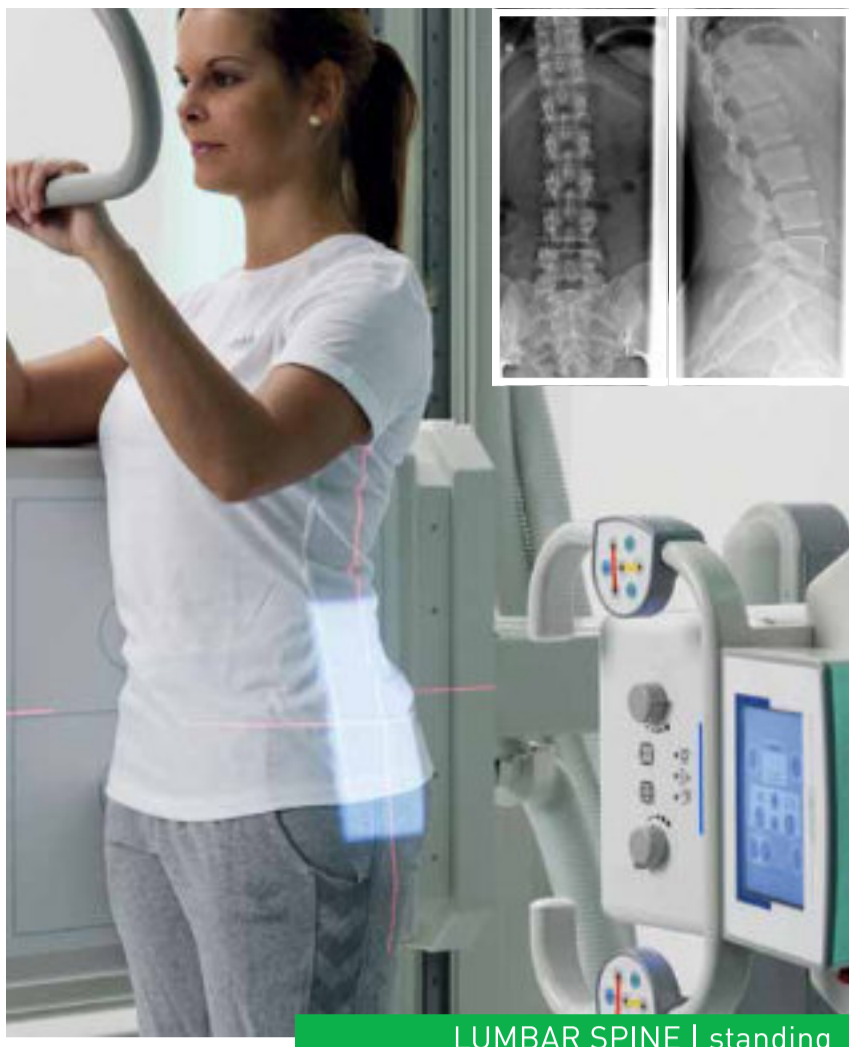
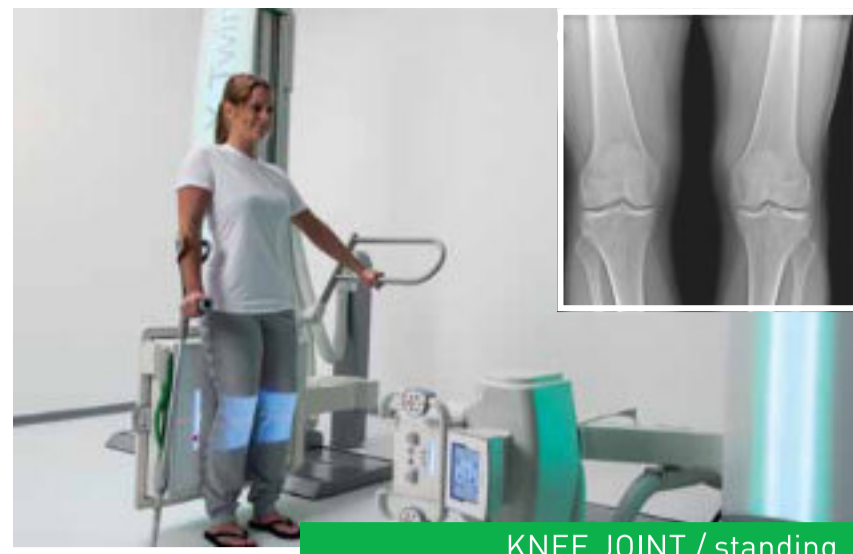
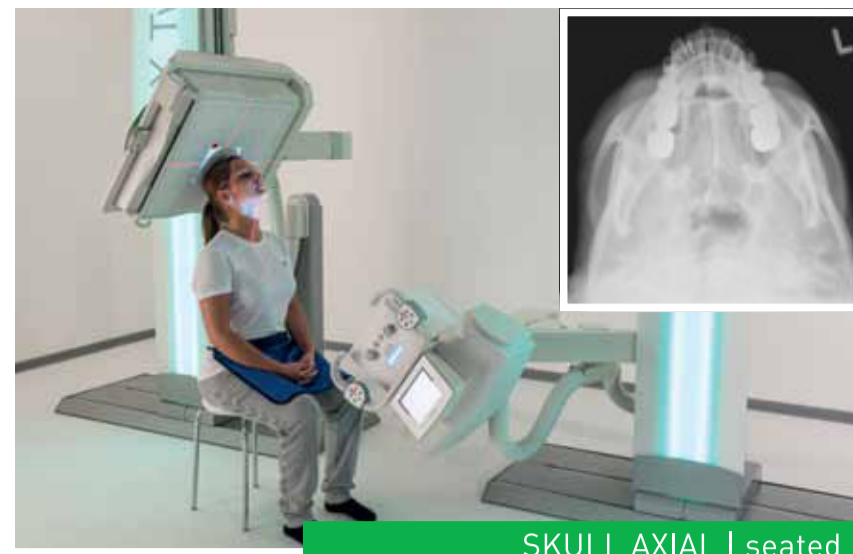

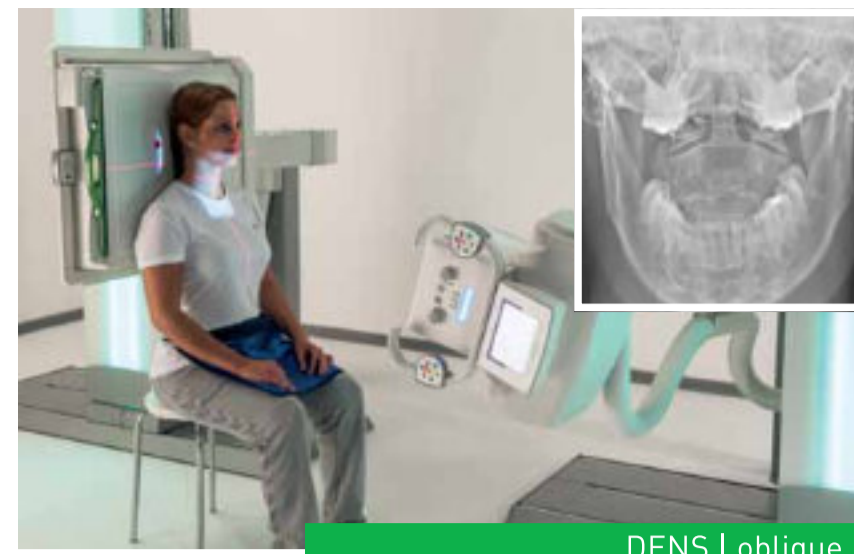LUMBAR SPINE | standing



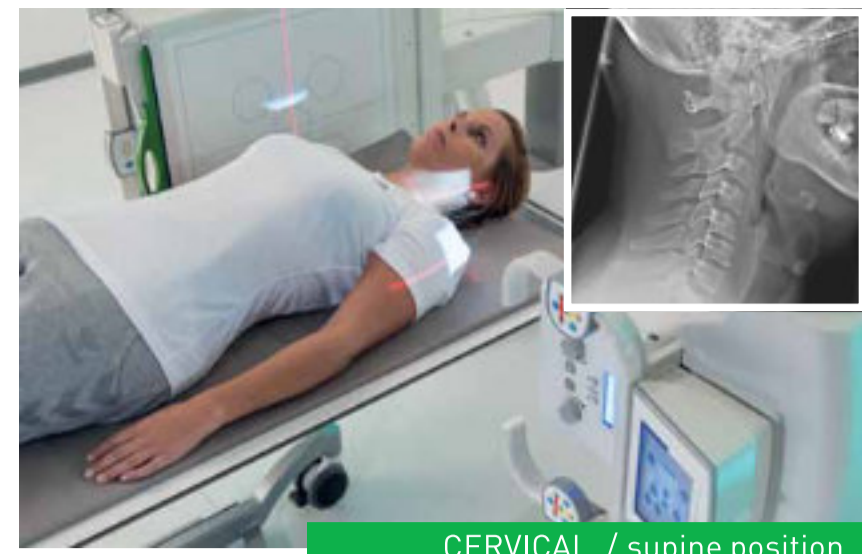KNEE JOINT | standing



SKULL AXIAL | seated



DENS | oblique

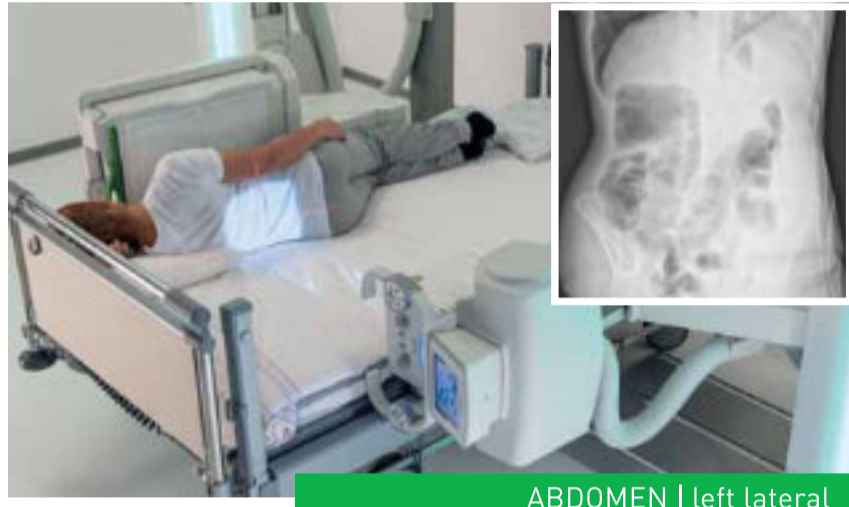

CERVICAL / supine position

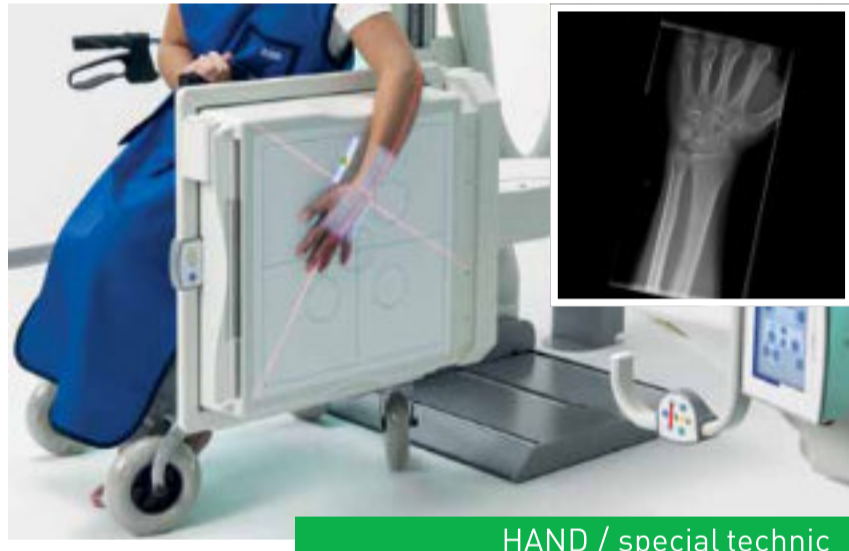X Twin

Digital X-ray System

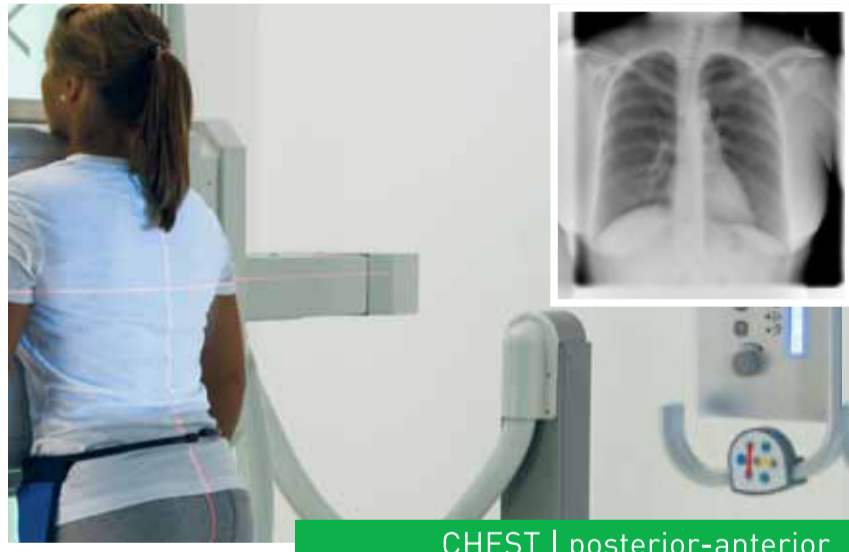roesys



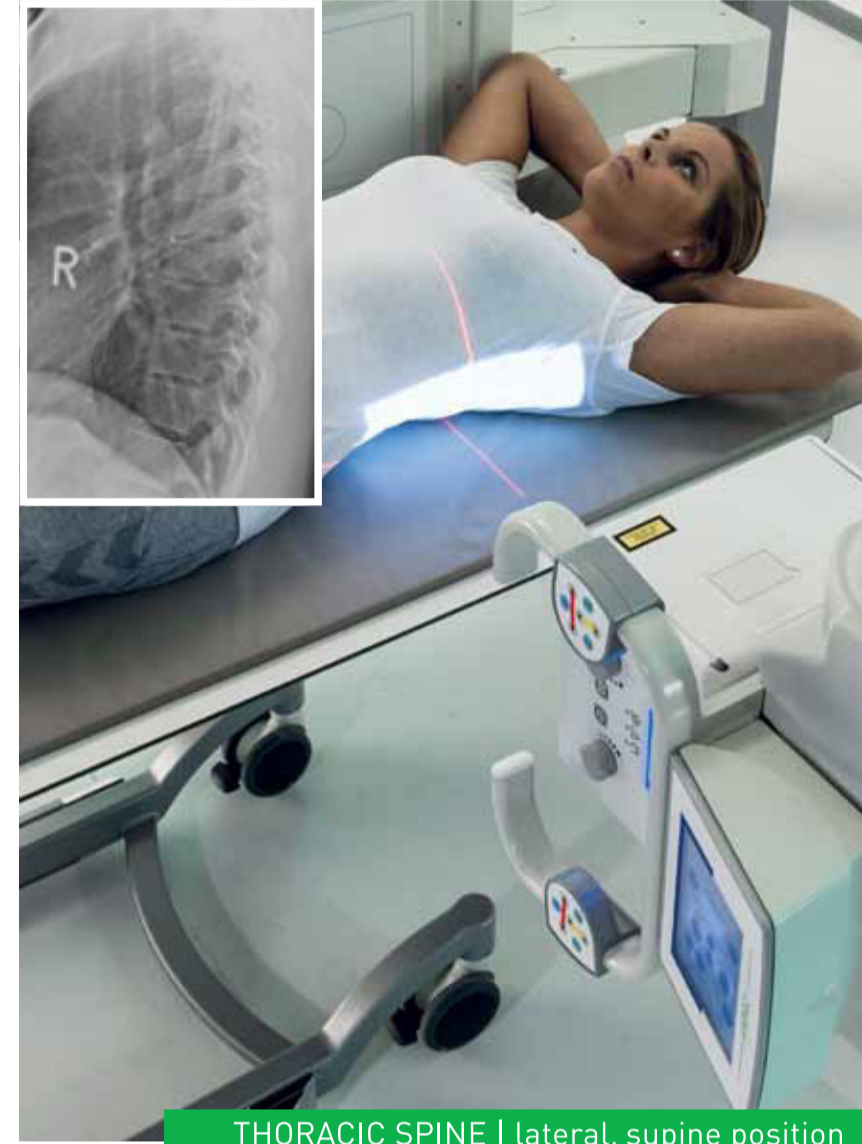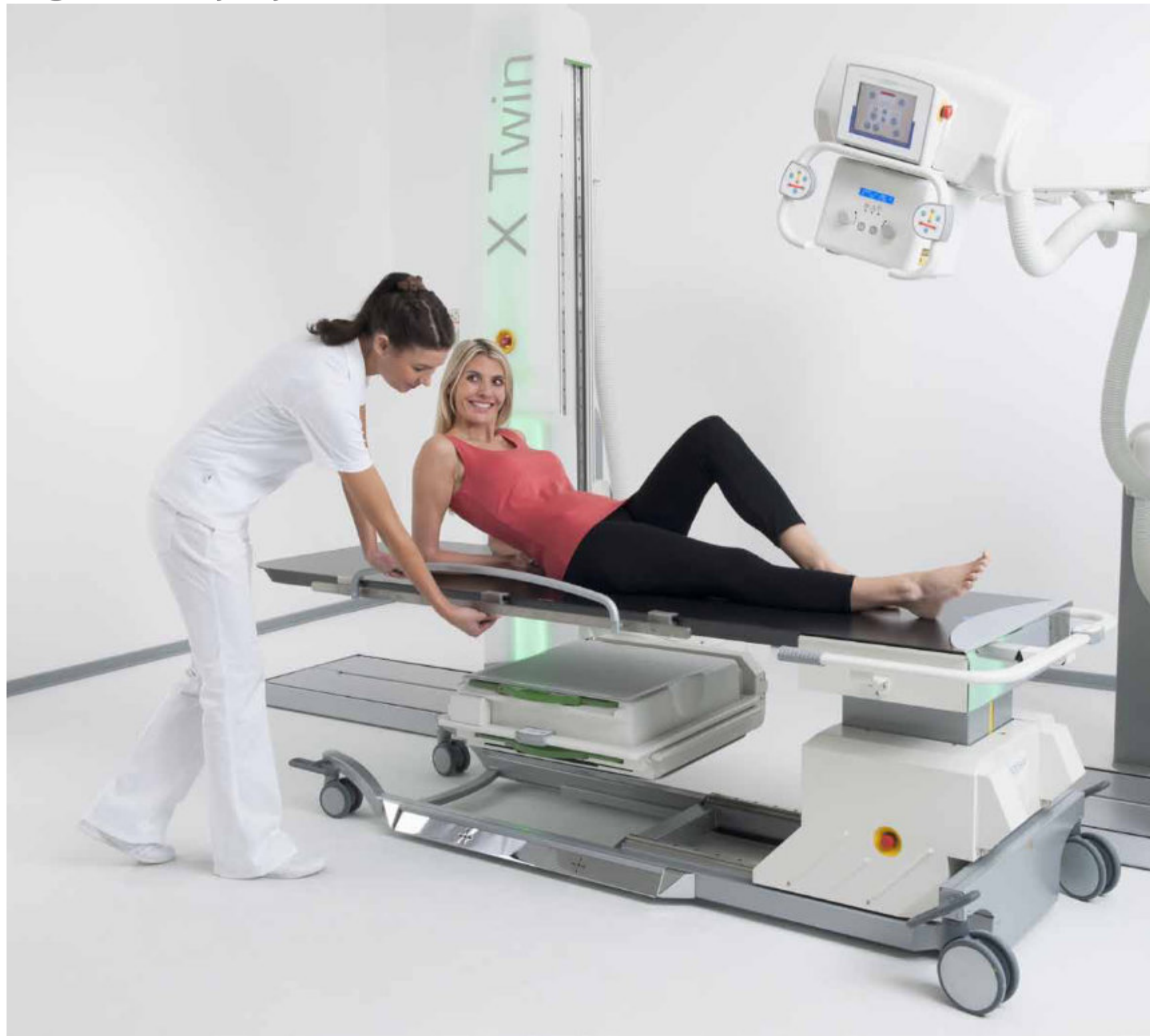ABDOMEN | left lateral



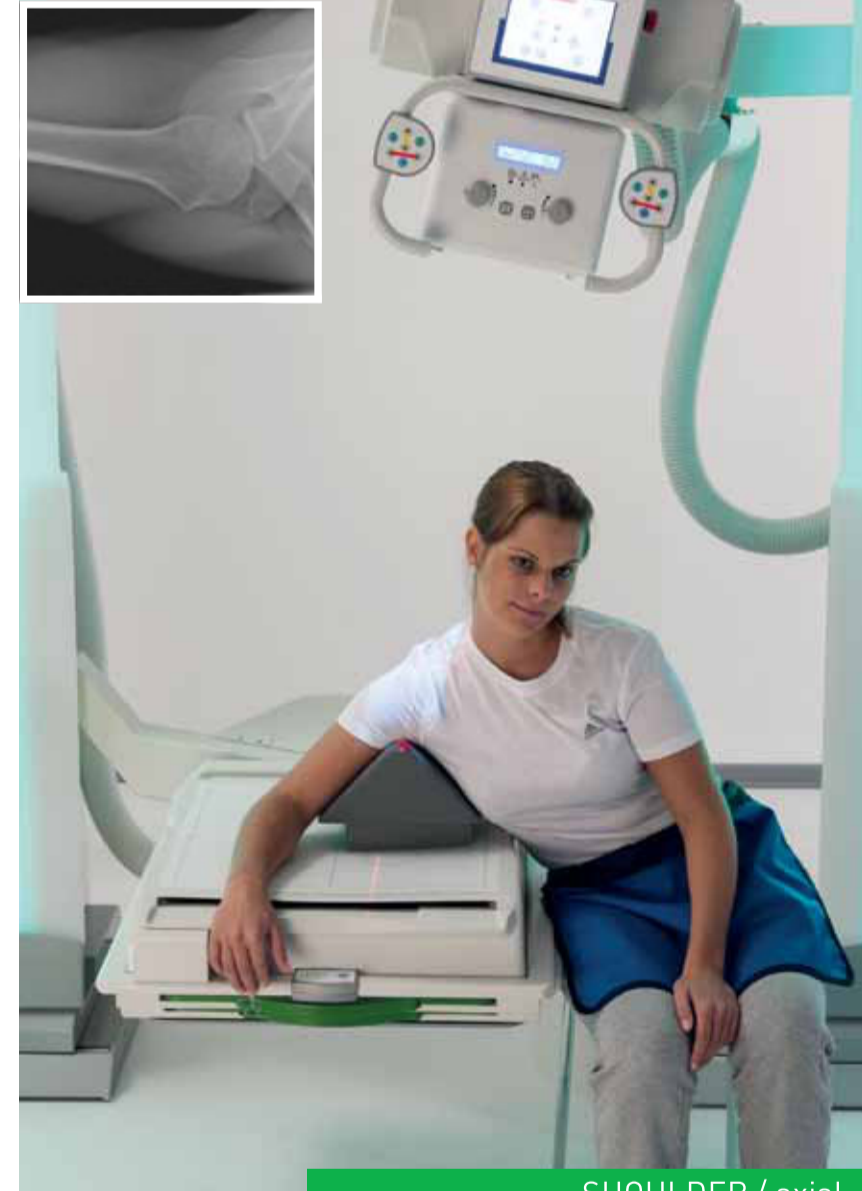
HAND / special technic



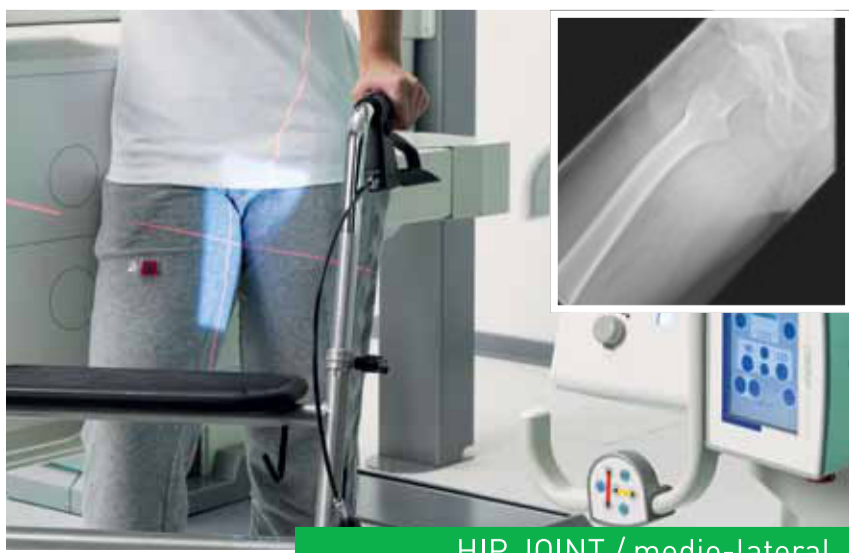CHEST | posterior-anterior



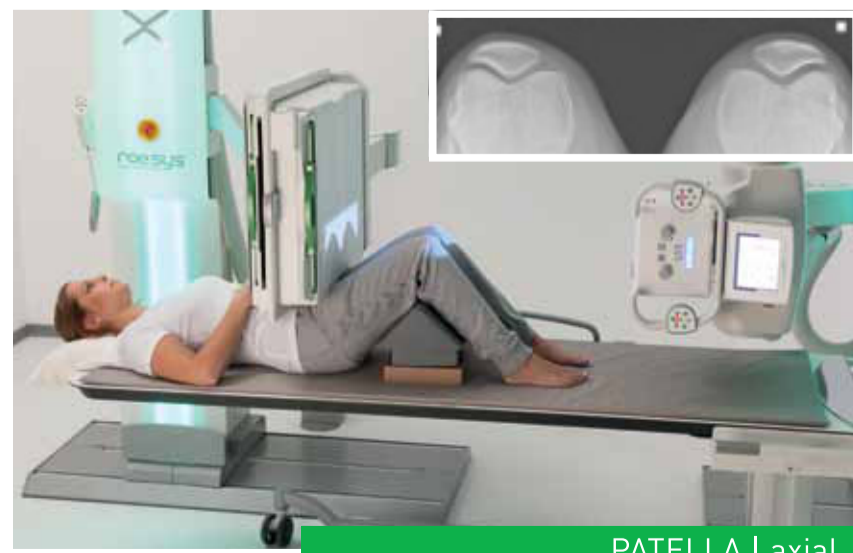THORACIC SPINE | lateral, supine position



SHOULDER / axial



HIP JOINT / medio-lateral



PATELLA | axial



WHOLE SPINE



STITCHING



WHOLE LEG